

Technical Note

Combined Double Bundle Anterior Cruciate Ligament Reconstruction and Anterolateral Ligament Reconstruction

Iñaki Mediavilla, M.D., Ph.D., Mikel Aramberri, M.D., Ph.D., Giovanni Tiso, M.D., and Jorge A. Murillo-González, Ph.D.

Abstract: A double-bundle anterior cruciate ligament (ACL) reconstruction associated with an anterolateral ligament (ALL) reconstruction is performed. The semitendinosus and gracilis are harvested. At knee maximum flexion, the anteromedial (AM) femoral tunnel is performed in the AM footprint area. Through the anterolateral portal, the tip of the outside-in femoral guide is placed in the posterolateral footprint area. The guide sleeve is pushed onto the lateral femoral cortex at the ALL attachment. At 110° knee flexion, the posterolateral-ALL tunnel is performed. The tibial ACL tunnel is performed as usual. The tibial guide is placed between the ALL tibial attachment and the tibial ACL tunnel entrance to perform the ALL tibial tunnel. The gracilis graft is introduced from caudal to cranial, achieving fixation with a 6-mm diameter screw (outside-in). The AM femoral fixation is achieved with a suspension device. ACL tibial graft fixation is achieved with a screw. Afterward, the gracilis is passed under the fascia lata to the tibial entry point. A 6-mm diameter screw is placed from the external cortex into the tibial ALL tunnel. The biomechanical advantage of the double-bundle ACL reconstruction with the biomechanical advantage of the ALL anatomic reconstruction is achieved.

The anterior cruciate ligament (ACL) reconstruction is a common procedure in orthopaedic surgery. The concept of combining a lateral extra-articular augmentation with an intra-articular reconstruction for the treatment of ACL injury emerged with the objective of decreasing the failure rate of either technique carried out in isolation.¹ Although it became popular, several studies suggested that intra-articular reconstruction of the ACL alone would be sufficient in the treatment of knee instability after isolated ACL tear.²

As the incidence of ACL reconstruction has increased significantly over the past 2 decades, so too have the revision rates for this procedure, which now represent a significant surgical burden.³ On the one hand, double-bundle (DB) reconstructions have been developed to improve control of global knee laxity.⁴ ACL single-bundle reconstructions have significantly more graft failures than the DB reconstructions.⁵ On the other hand, lateral extra-articular tenodesis in combination with ACL reconstruction in the primary setting has been proposed as a way of potentially improving rotational stability and clinical outcomes compared with isolated ACL reconstructions.⁶

A simple ACL and the anterolateral ligament (ALL) reconstructions using hamstring tendons has already been published.⁷ In this work, a double-bundle ACL reconstruction associated to an anterolateral ligament reconstruction is developed (Fig 1; Video 1; Table 1).

From the University Hospital of Basurto (I.M.), Bilbao; Alai Sports Medicine Clinic (M.A., G.T.); and Department of Human Anatomy and Embriology, Faculty of Medicine, Complutense University of Madrid (J.A.M-G.), Madrid, Spain.

The authors report the following potential conflicts of interest or sources of funding: M.A. receives support from Stryker (consultant only for shoulder courses). Full ICMJE author disclosure forms are available for this article online, as [supplementary material](#).

Received March 20, 2018; accepted April 13, 2018.

Address correspondence to Iñaki Mediavilla, M.D., Ph.D., University Hospital of Basurto, Montevideo Avenue, 18 48013 Bilbao, Spain. E-mail: imediavilla@aitira.com

© 2018 by the Arthroscopy Association of North America. Published by Elsevier. This is an open access article under the CC BY-NC-ND license (<http://creativecommons.org/licenses/by-nc-nd/4.0/>).

2212-6287/18362

<https://doi.org/10.1016/j.eats.2018.04.011>

Surgical Technique

Patient Setup

The patient is placed supine on an operative table in the standard arthroscopy position with a lateral post just proximal to the knee at the level of the padded tourniquet, and a foot roll to keep the knee flexion at 90° (Fig 2).

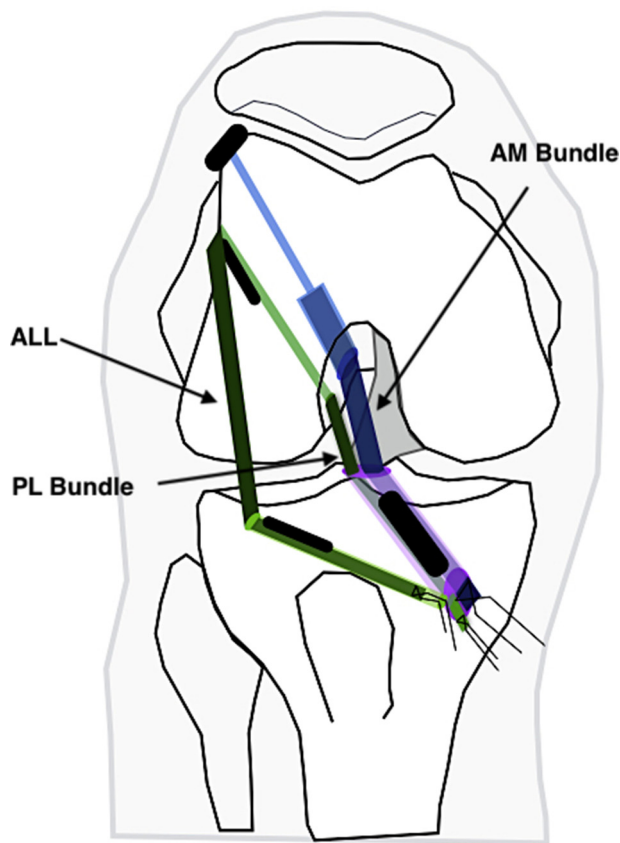


Fig 1. Diagram of technique performed on a right knee. A double-bundle anterior cruciate ligament reconstruction associated to an ALL reconstruction is developed. The fixation devices have been drawn in black. (ALL, anterolateral ligament; AM, anteromedial; PL, posterolateral.)

Bony Landmarks

Four bony landmarks are marked (Fig 2): the head of the fibula, the joint line, the Gerdy tubercle, and the lateral epicondyle.

Graft Harvest and Preparation

A skin incision is made anteromedially to the anterior tibial tuberosity. The semitendinosus and gracilis are harvested with a standard tendon stripper. The ends of the gracilis are prepared separately with traction threads (No. 1 Ethibond sutures). Usually, a 3-strand graft is prepared. One third of the tendon is loaded in a suspensory device according to the marks. The semitendinosus graft is then tripled over itself and tagged with No. 1 Ethibond sutures to tubularize the graft. This graft preparation allows an ACL graft with a diameter of 8 to 9 mm (becoming the anteromedial [AM] graft) to be obtained.

Arthroscopic Exploration

Routine view of the knee arthroscopy is performed using AM and anterolateral portals.

Table 1. Step-by-Step Details of Technique

1. Patient positioning
 - a. The patient is placed supine on an operative table with a lateral post just proximal to the knee at the level of the padded tourniquet and a foot roll to keep the knee flexion at 90°.
2. Graft harvest and preparation:
 - a. Using a tripled semitendinosus typically provides a graft between 7 and 9 mm.
 - b. Using single gracilis typically provides a 4.5-mm graft.
3. Drilling tunnels
 - a. Drilling of femoral AM tunnel

The center of the AM footprint area must be selected. At this point, a microfracture must be performed before drilling.

Drilling is performed in an outside-in manner using the appropriate over-the-top femoral guide through the AM portal. As usual, after passing a size 4.5 cannulated reamer through the lateral femoral cortex (at maximum flexion), the AM graft diameter, and 25-mm deep tunnel is performed.
 - b. Drilling of femoral PL and ALL tunnel

The drill guide is placed externally at the femoral ALL isometric point and internally at the center of the PL footprint.

Drilling is performed (4.5-mm diameter tunnel) in an outside-in manner with the knee in 100° to 110° flexion.
 - c. Drilling of tibial ACL tunnel

The tibial tunnel is drilled with a 55° angled ACL guide inserted into the joint through the AM portal and taken from the external cortex into the ACL insertion (as usual).
 - d. Drilling of tibial ALL tunnel

ACL guide is used to perform a tunnel between the midpoint between the Gerdy tubercle and fibular head (1 cm distal to the joint line) and the entry to the tibial tunnel.
4. Graft passage and fixation
 - a. PL-ALL graft passage and femoral fixation

From the tibial tunnel entry point, the gracilis graft is pulled up with the traction threads into the joint. It enters the PL tunnel until exiting through the femoral lateral cortex. One end of the graft remains at the entrance of the tibial tunnel.

A 6-mm diameter degradable screw is inserted from the femoral lateral cortex entry.
 - b. AM graft passage and femoral fixation

The AM graft is pulled up until the suspension device is attached to the femoral cortex and accurately position the soft-tissue graft in the femoral tunnel is achieved.
 - c. ALL graft passage and tibial fixation

The traction threads of the gracilis graft are passed percutaneously under the fascia lata to the tibial anterolateral incision.

From external tibial cortex, a 6-mm diameter interference screw is placed into the femoral tunnel using a nitinol guidewire with the knee in full extension.
 - d. ACL tibial fixation:

With the knee at 30° of flexion, pass a 1.1-mm nitinol guidewire through the tibial tunnel and insert the suitable interference screw to achieve tibial fixation.

ACL, anterior cruciate ligament; ALL, anterolateral ligament; AM, anteromedial; PL, posterolateral.

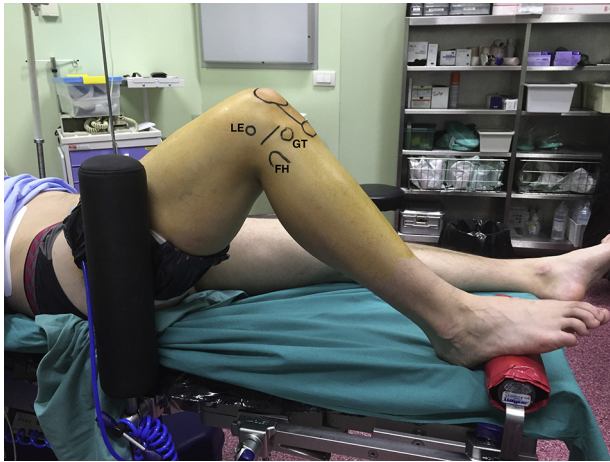

Fig 2. Patient positioning: the patient is placed supine on an operative table in the standard arthroscopy position with a lateral post just proximal to the right knee at the level of the padded tourniquet. (LE, lateral epicondyle; GT, Gerdy tubercle; FH, fibula head.)

Drilling Tunnels

Drilling of Femoral AM Tunnel. With the knee at 90° flexion and after visualizing the “over-the-top” position, the appropriate over-the-top femoral guide (to preserve a 2-mm posterior wall) is inserted through the AM portal. A guide pin is placed in an inside-out manner to perform a microfracture in the entry point of the femoral AM tunnel. The guide is withdrawn slightly backward. Once the entry point is recognized, the joint can be flexed completely and the guide pin can be inserted until the lateral cortex of the lateral femoral condyle. A 4.5 cannulated reamer is passed over the guide pin and a tunnel is drilled up to and through the lateral cortex of the femur. The length of the tunnel is measured. Using a guide pin, the femoral AM tunnel is created using a drill bit of the same diameter as the AM graft and 25 mm deep (Fig 3A).

Drilling of Femoral Posterolateral and ALL Tunnel. An outside-in femoral guide Maestro (Smith & Nephew) is used. The arthroscope is inserted through the AM portal and the end of the guide through the anterolateral portal (Fig 4A). The tip of the guide must be placed in the anterior perimeter of the AM tunnel. The guide offset should preserve a rear wall of 2 mm with respect to the AM tunnel. The guide sleeve is pushed onto the lateral femoral cortex at the appropriate point marked for optimal ALL isometry. With the knee in 110° flexion, a guide pin is placed in an outside-in manner, from the ALL isometric point on the lateral epicondyle to the femoral origin of the posterolateral (PL) bundle (Fig 4B). Once the guide pin is placed, a 4.5-mm-diameter tunnel is completed (Fig 3B).

Drilling of Tibial ACL Tunnel. The tibial tunnel is drilled with a 55° angled ACL guide inserted into the joint through the AM portal and aiming from the external cortex to the ACL insertion. Reaming is performed using the previously measured ACL size reamer (AM graft + gracilis) (Fig 3C).

Drilling of Tibial ALL Tunnel. A standard tip aimer ACL tibial guide is used after adjusting its angulation. The guide sleeve is inserted through a skin incision at the midpoint between the Gerdy tubercle and fibular head that is 1 cm distal to the joint line. The tip of the guide is placed in the internal cortex in the entrance to the tibial tunnel. Drill a 2.4-mm guide pin through the guide (Fig 5). Ream over the guide pin with the 4.5-mm reamer (Fig 3D).

Graft Passage and Fixation

PL-ALL Graft Passage and Femoral Fixation

The gracilis is introduced from the caudal to cranial direction through the ACL tibial tunnel and through the PL femoral tunnel. From the external femoral cortex, a

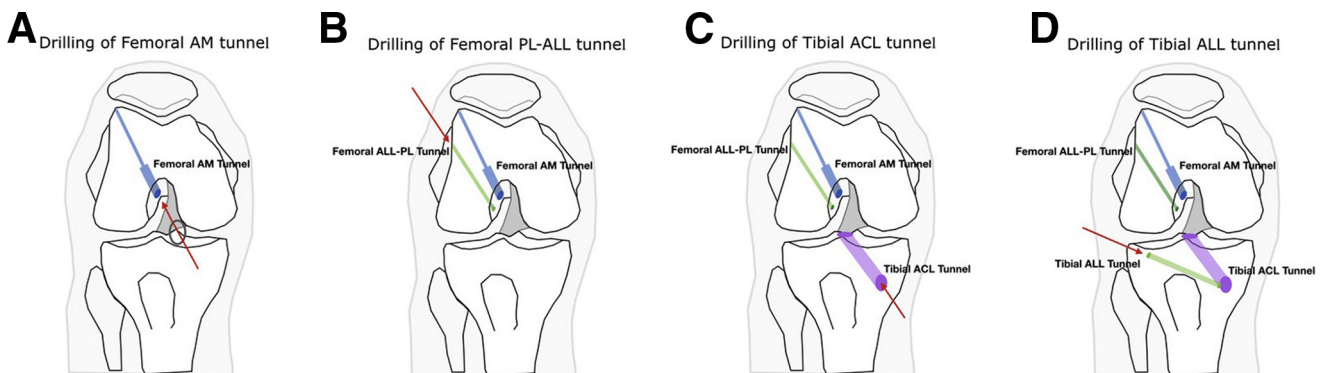


Fig 3. Drilling tunnels (right knee). (A) Drilling of femoral AM tunnel (blue; gray circle, AM portal; red arrow, drilling direction). (B) Drilling of femoral PL-ALL tunnel (green; red arrow, drilling direction). (C) Drilling of tibial ACL tunnel (purple; red arrow, drilling direction). (D) Drilling of tibial ALL tunnel (light green; red arrow, drilling direction). (ALL, anterolateral ligament; AM, anteromedial; PL, posterolateral.)

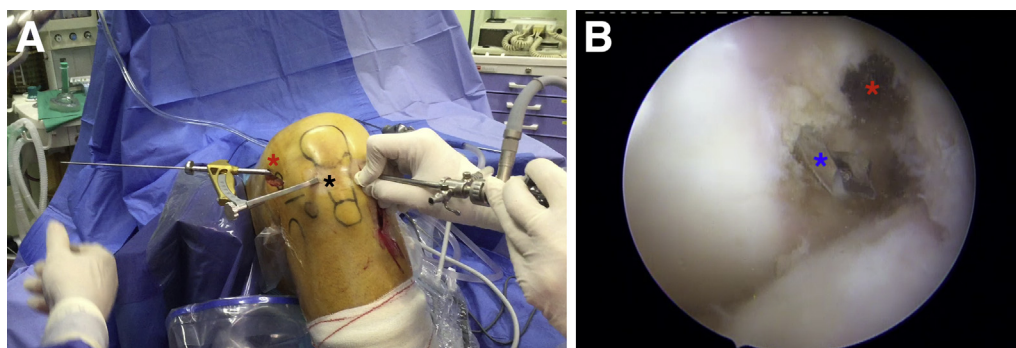


Fig 4. (A) Drilling of femoral PL and ALL tunnel (extra-articular view of the right knee): an outside-in femoral guide Maestro (Smith & Nephew) is inserted through the AM portal (black asterisk). The guide sleeve is pushed onto the lateral femoral cortex at the appropriate point marked for optimal ALL isometry (red asterisk). (B) Drilling of femoral PL and ALL tunnel (intra-articular view of the right knee): a guide pin is inserted through the lateral femoral condyle; its tip is located at the footprint area for the PL bundle (blue asterisk). The guide offset preserves a rear wall with respect to the anteromedial tunnel (red asterisk). (ALL, anterolateral ligament; PL, posterolateral.)

6-mm diameter interference screw is placed into the femoral tunnel using a nitinol guidewire (Fig 6A).

AM Graft Passage and Femoral Fixation

The AM graft is also introduced from the caudal to cranial direction. After engaging the implant on the lateral femoral cortex, the AM graft is placed into the AM femoral tunnel (Fig 6B).

Tibial Fixation of ACL Tibial Graft

With the knee at 30° flexion, pass a 1.1-mm nitinol guidewire through the tibial tunnel, and insert the suitable interference screw to achieve tibial fixation (Fig 6C).

Tibial Fixation of ALL Tibial Graft

The traction threads of the gracilis graft are passed and retrieved percutaneously under the fascia lata (by use of an arthroscopic grasper) to the tibial anterolateral incision. Then, the traction threads of the gracilis are retrieved through the ALL tibial tunnel from the lateral to medial tibial cortex. From the external tibial cortex, a 6-mm diameter interference screw is placed into the tibial tunnel using a nitinol guidewire with the knee in full extension (Fig 6D).

Postoperative Course

A routine ACL rehabilitation program is carried out. Crutches are used for 3 to 4 weeks and a brace for 4 to 6 weeks.

Discussion

The main advantage of this technique is the possibility to perform a DB ACL reconstruction associated with the ALL anatomic reconstruction using regular hamstring grafts. The biomechanical advantage of the DB ACL reconstruction is the anterior control of knee instability associated with the biomechanical advantage of the

ALL anatomic reconstruction in anterolateral control of the knee instability (Table 2).

Because transtibial SB reconstructions can lead to some degree of rotational instability when the knee is close to extension,⁸ it has been proposed to perform ACL reconstruction via 2 independent bundles (DB): the AM bundle and the PL bundle.^{4,9} Also, to resolve this rotational instability, the ALL anatomic reconstruction has been advocated.¹⁰ It originates posterior and proximal to the lateral epicondyle¹¹ and inserts midway between the Gerdy tubercle and fibular head in the tibial bone.¹²

ACL reconstruction techniques have evolved from nonanatomic to anatomic and individualized techniques to maximally reproduce either the anatomy of the knee or its biomechanical behavior. In addition, there are patients with high expectations about using their knee after ACL surgery (Table 2). Apart from that,

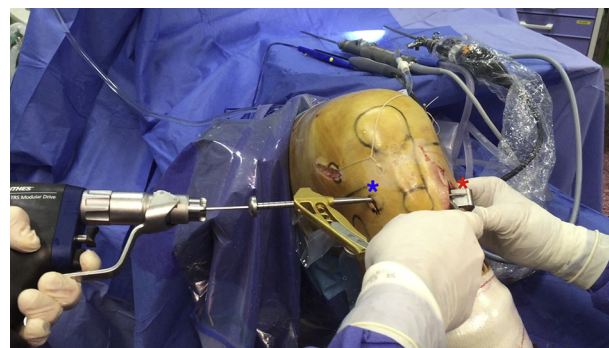


Fig 5. Drilling of tibial anterolateral ligament tunnel (extra-articular view of the right knee). A standard tip aimer anterior cruciate ligament tibial guide is used. The guide sleeve is inserted through a skin incision at the midpoint between the Gerdy tubercle and fibular head and 1 cm distal to the joint line (blue asterisk). The tip of the guide is placed in the internal cortex in the entrance to the tibial tunnel (red asterisk).

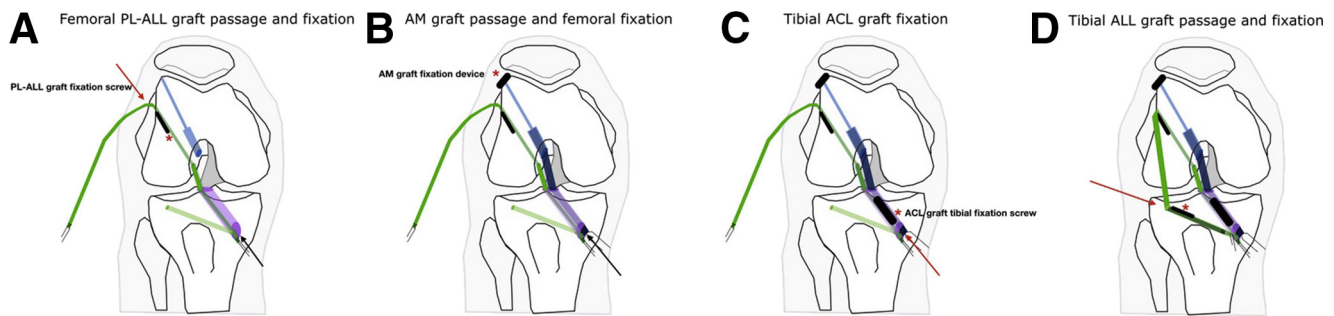


Fig 6. Graft passage and fixation (right knee). (A) Femoral PL-ALL graft (green) passage and fixation. (black arrow, passage direction; red arrow, fixation direction; red asterisk, PL-ALL fixation screw). (B) AM graft passage and femoral fixation (black arrow, passage direction; red asterisk, AM fixation device). (C) Tibial ACL graft fixation (red arrow, fixation direction; red asterisk, ACL fixation screw). (D) Tibial ALL graft passage and fixation (red arrow, fixation direction; red asterisk tibial ALL fixation screw). (ALL, anterolateral ligament; AM, anteromedial; PL, posterolateral.)

specifically, it seems that female athletes have higher incidence of ACL injuries.¹³ Looking for better and more personalized surgical solutions, DM and ALL ACL reconstruction provides the best qualities of the 2 reconstruction models.

Two femoral tunnels are performed via an anteromedial portal. To perform the AM tunnel, the proximal area of the ACL footprint is selected because of its isometric conditions.^{14,15} The maximum flexion angle leads the guide pin proximally on the lateral femoral cortex. To perform the PL tunnel, the knee flexion angle is smaller in this moment, which creates the divergence of the tunnels.

With a diameter of 18 mm (on average), the femoral footprint area is large enough for 2 tunnels to be placed.^{16,17} The femoral guide should provide an appropriate 2-mm bone bridge thickness between the AM and PL tunnels. The distance between the 2 tunnel centers has shown a strong positive correlation with body height (not with sex).¹⁸ The PL tunnel has an entry point at the center of the PL area and an exit point

at the femoral attachment of the ALL on the lateral cortex of the lateral femoral condyle.

In 2 locations, there is a risk of overlap tunnels. Because femoral tunnels are performed in different knee flexion angles, there is a lower risk of tunnels overlapping on the femoral lateral cortex. It may be more difficult preserving a bony bridge between the 2 intra-articular apertures. Only in patients with relatively short stature (<160 cm for men; <155 cm for women), the AM and PL tunnel apertures are considered to be at a risk of overlap with the DB technique (Table 2). Alternatively, surgeons should select the combined ACL single bundle and ALL reconstruction⁷ from the beginning in those patients with short stature. Also, 1 limitation could be a gracilis graft that is not long enough for extra-articular reconstruction.

References

1. Clancy WG Jr, Nelson DA, Reider B, Narechania RG. Anterior cruciate ligament reconstruction using one-third of the patellar ligament, augmented by extra-articular tendon transfers. *J Bone Joint Surg Am* 1982;64:352-359.
2. Strum GM, Fox JM, Ferkel RD, et al. Intraarticular versus intraarticular and extraarticular reconstruction for chronic anterior cruciate ligament instability. *Clin Orthop Relat Res* 1989;188-198.
3. Denti M, Lo Vetere D, Bait C, Schönhuber H, Melegati G, Volpi P. Revision anterior cruciate ligament reconstruction: Causes of failure, surgical technique, and clinical results. *Am J Sports Med* 2008;10:1896-1902.
4. Colombet P, Robinson J, Jambou S, Allard M, Bousquet V, the Lavigne C. Two-bundle, four-tunnel anterior cruciate ligament reconstruction. *Knee Surg Sports Traumatol Arthrosc* 2005;9:1-8.
5. Järvelä S, Kiekara T, Suomalainen P, Järvelä T. Double-bundle versus single-bundle anterior cruciate ligament reconstruction: A prospective randomized study with 10-year results. *Am J Sports Med* 2017;45:2578-2585.
6. Devitt BM, Bell SW, Ardern CL, et al. The role of lateral extra-articular tenodesis in primary anterior cruciate ligament reconstruction: A systematic review with

Table 2. Advantages, Disadvantages, Indication, Risk, and Limitations of the DB ACL-ALL Reconstruction

Advantages
Biomechanical qualities of DB-ACL reconstruction and ALL reconstruction (additional anterolateral stability)
Anatomic position of each ligament can be achieved because they are performed independently using their original footprints
Disadvantages
More complicated and expensive surgery
Indication
Pivoting or high-demand patients
Younger patients
Sportswomen
Risk
Overlap of tunnel apertures
Limitations
Short stature (<160 cm for males; <155 cm for females)

ACL, anterior cruciate ligament; ALL, anterolateral ligament; DB, double bundle.

- meta-analysis and best-evidence synthesis. *Orthop J Sports Med* 2017;5. 2325967117731767.
7. Sonnery-Cottet B, Daggett M, Helito CP, Fayard JM, Thauinat M. Combined anterior cruciate ligament and anterolateral ligament reconstruction. *Arthrosc Tech* 2016;5:e1253-e1259.
 8. Tashman S, Collon D, Anderson K, Kolowich P, Anderst W. Abnormal rotational knee motion during running after anterior cruciate ligament reconstruction. *Am J Sports Med* 2004;32:975-983.
 9. Buoncrisiani AM, Tjoumakaris FP, Starman JS, Ferretti M, Fu FH. Anatomic double-bundle anterior cruciate ligament reconstruction. *Arthroscopy* 2006;22:1000-1006.
 10. Sonnery-Cottet B, Saithna A, Cavalier M, et al. Anterolateral ligament reconstruction is associated with significantly reduced ACL graft rupture rates at a minimum follow-up of 2 years: A prospective comparative study of 502 patients from the SANTI Study Group. *Am J Sports Med* 2017;45:1547-1557.
 11. Imbert P, Lutz C, Daggett M, et al. Isometric characteristics of the anterolateral ligament of the knee: A cadaveric navigation study. *Arthroscopy* 2016;32:2017-2024.
 12. Claes S, Vereecke E, Maes M, Victor J, Verdonk P, Bellemans J. Anatomy of the anterolateral ligament of the knee. *J Anat* 2013;223:321-328.
 13. Ferrari JD, Bach BR Jr, Bush-Joseph CA, Wang T, Bojchuk J. Anterior cruciate ligament reconstruction in men and women: An outcome analysis comparing gender. *Arthroscopy* 2001;17:588-596.
 14. Sapega AA, Moyer RA, Schneck C, Komalahiranya N. Testing for isometry during reconstruction of the anterior cruciate ligament. Anatomical and biomechanical considerations. *J Bone Joint Surg (Am)* 1990;72:259-267.
 15. Smith JO, Yaseen S, Risebury MJ, Wilson AJ. Femoral and tibial tunnel positioning on graft isometry in anterior cruciate ligament reconstruction: A cadaveric study. *J Orthop Surg (Hong Kong)* 2014;22:318-324.
 16. Odenstein M, Gillquist J. Functional anatomy of the anterior cruciate ligament and a rationale for reconstruction. *J Bone Joint Surg (Am)* 1985;67:257-262.
 17. Kopf S, Musahl V, Tashman S, Szczodry M, Shen W, Fu FH. A systematic review of the femoral origin and tibial insertion morphology of the ACL. *Knee Surg Sports Traumatol Arthrosc* 2009;17:213-219.
 18. Tashiro Y, Okazaki K, Iwamoto Y. Evaluating the distance between the femoral tunnel centers in anatomic double-bundle anterior cruciate ligament reconstruction using a computer simulation. *Open Access J Sports Med* 2015;6:219-224.